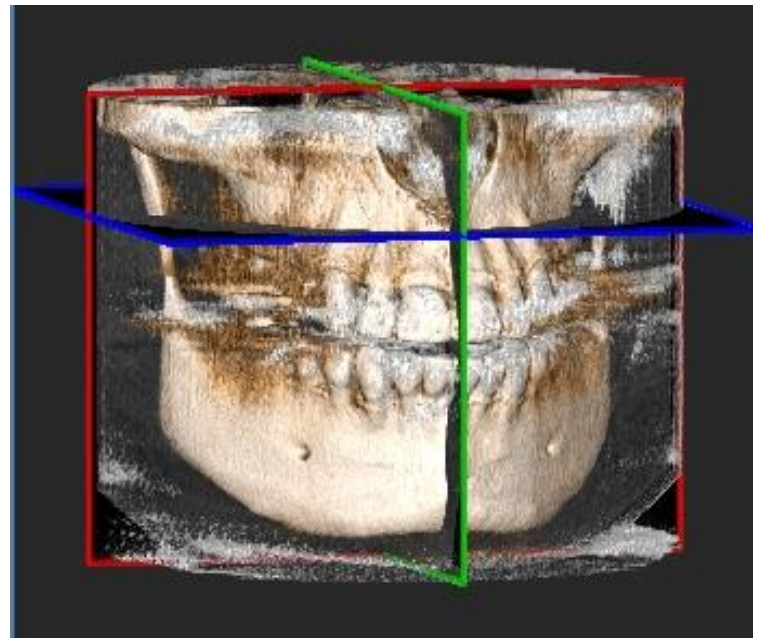
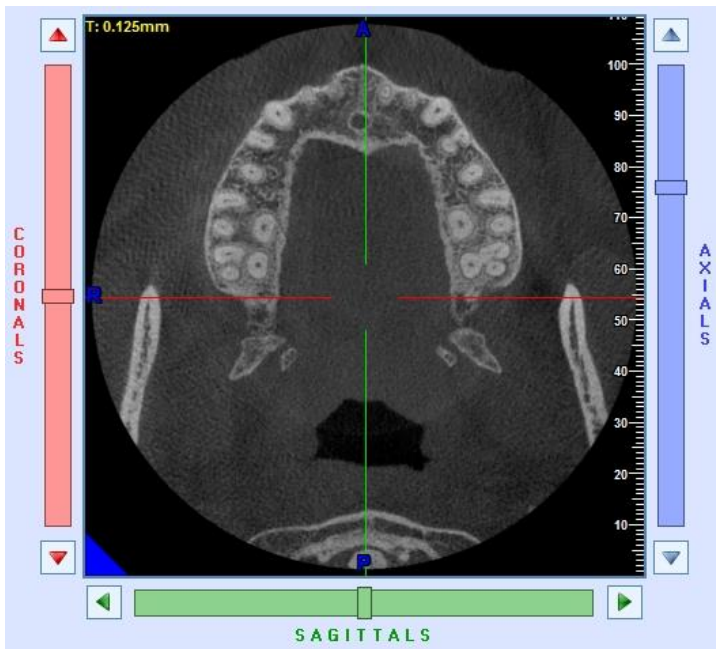
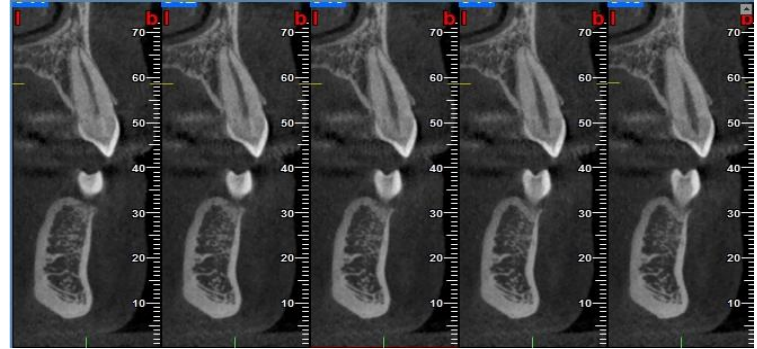
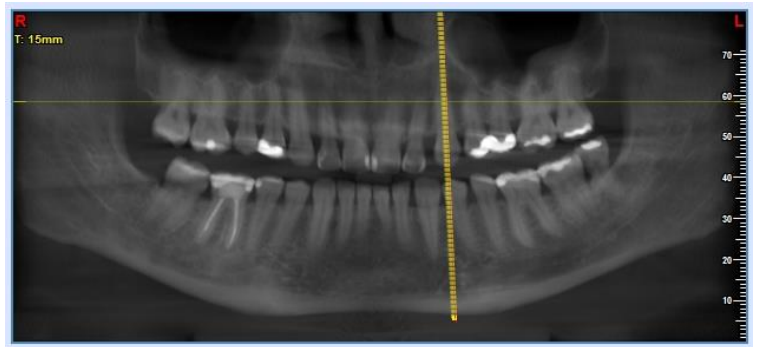
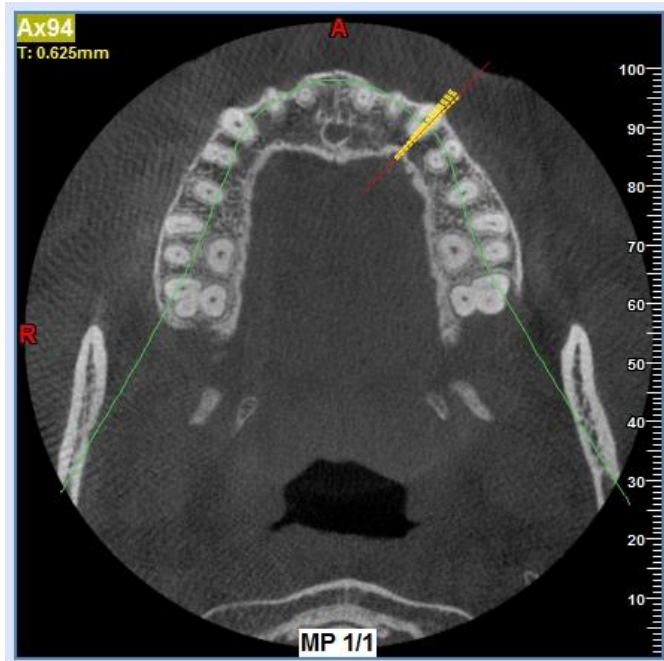
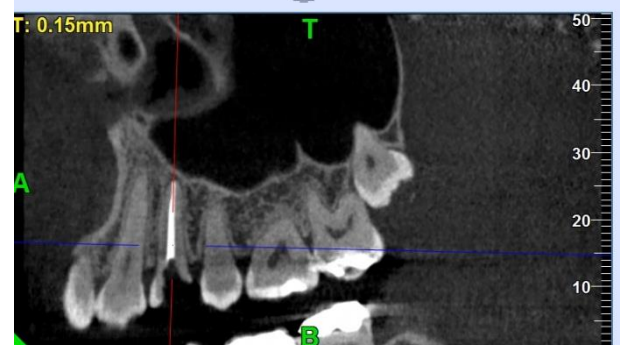
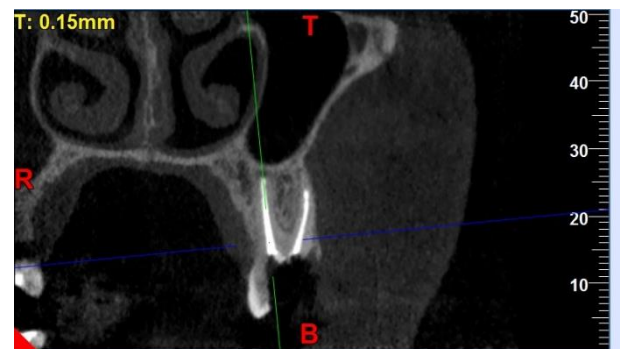
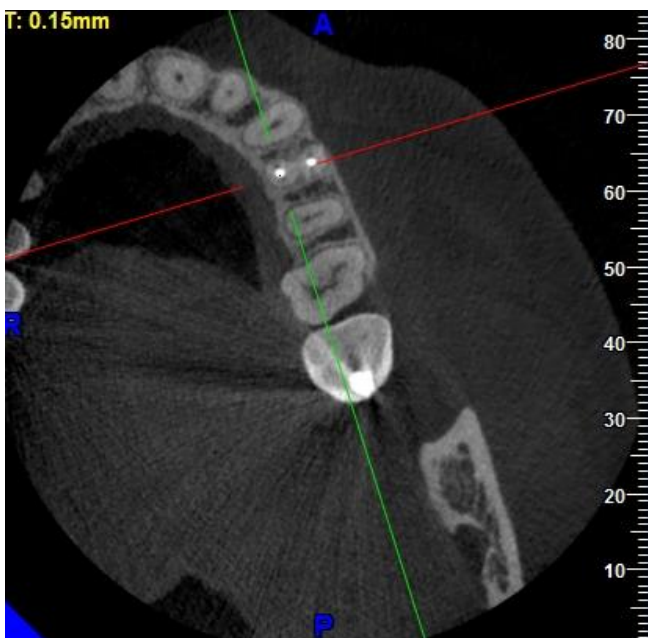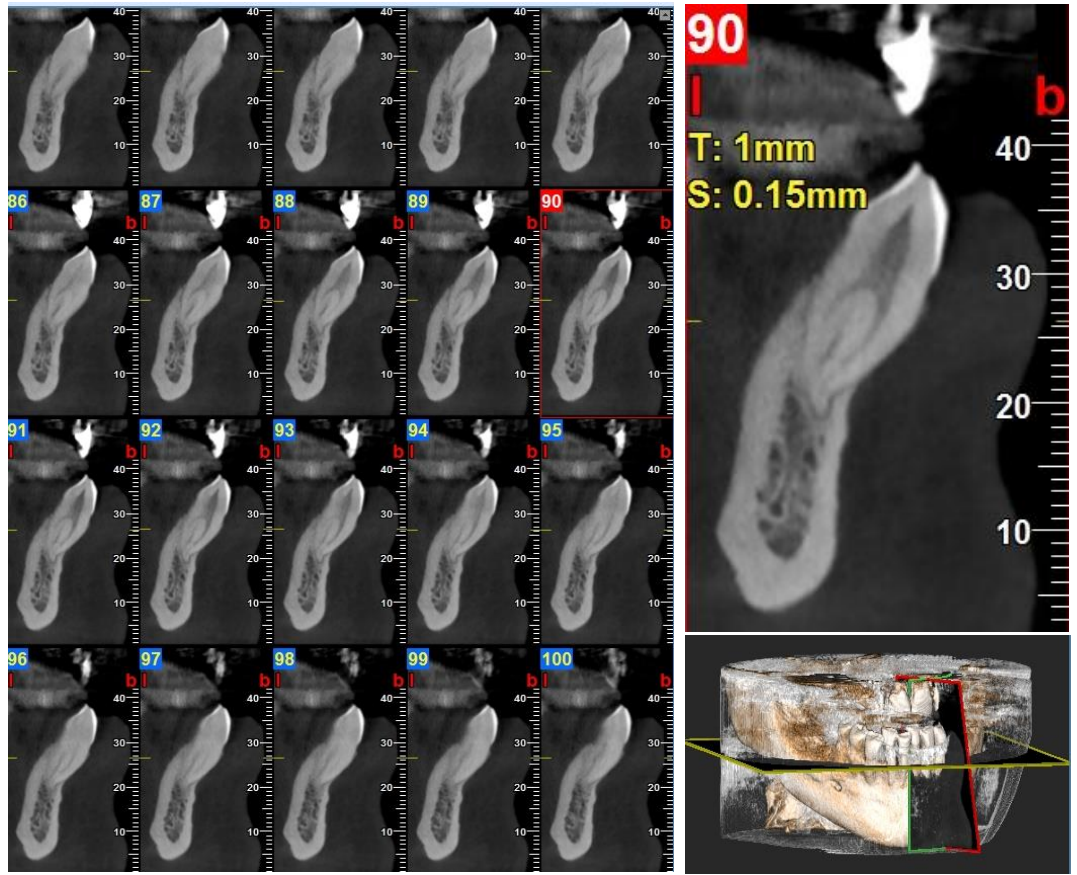
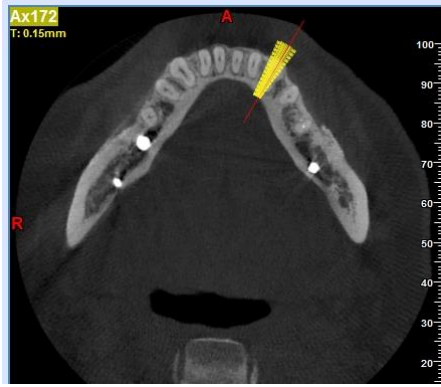
Zub 23, tvar a průběh k. k., FOV 11x8, rozlišení 150 μ m:



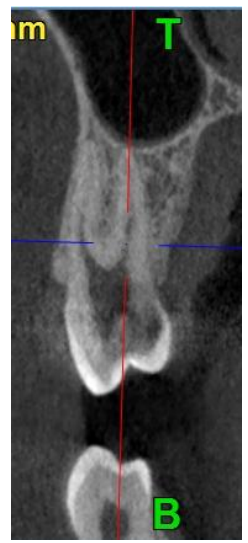
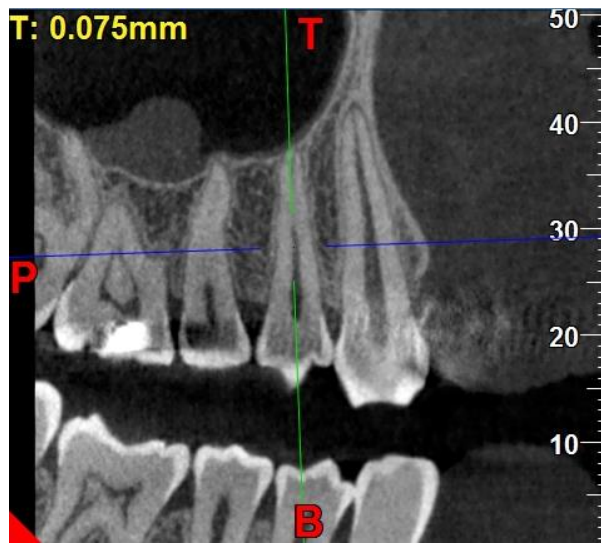
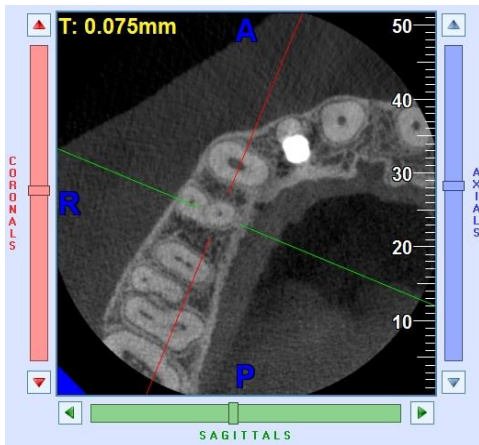
Distální kořen zubu 24, FOV 8x5, rozlišení 150 μ m:



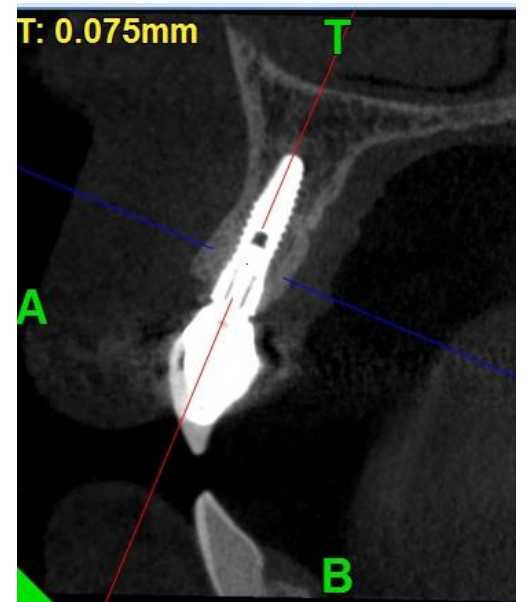
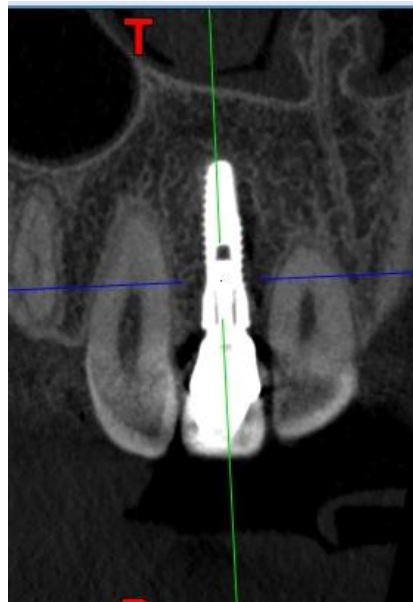
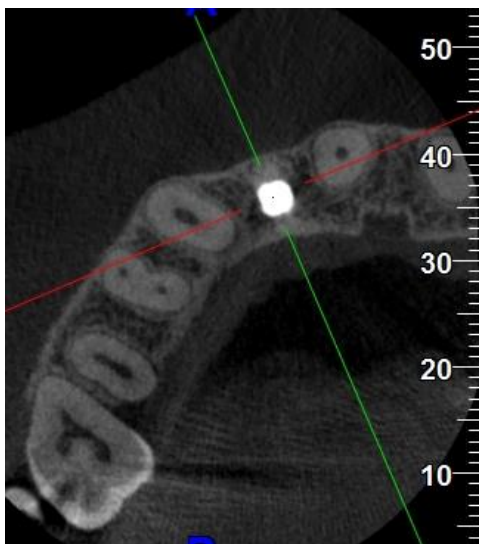
Endodont zubu 33,
FOV 11x8, rozlišení 150 µm:



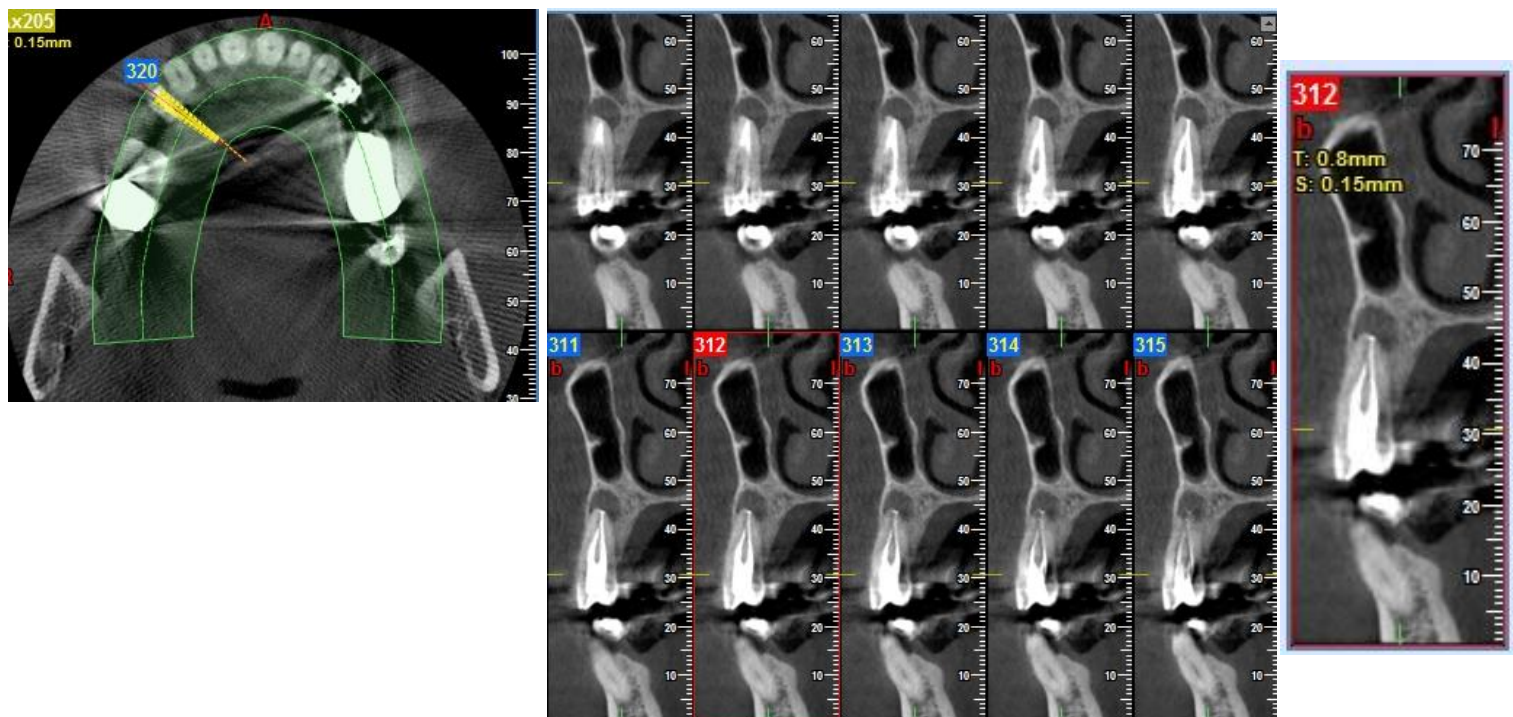
Palatinální kořen zubu 14 a kořen 13,
FOV 5x5, rozlišení 75 µm:



Implantát 12, **FOV 5x5, rozlišení 75 µm:**



Zub 14, periapikální nále, endodontická výplň kořenů, FOV 11x8, rozlišení 150 μ m:



Čelistní a ethmoidální dutiny, hlavní nosní dutina, FOV 11x8, rozlišení 150 μ m:

